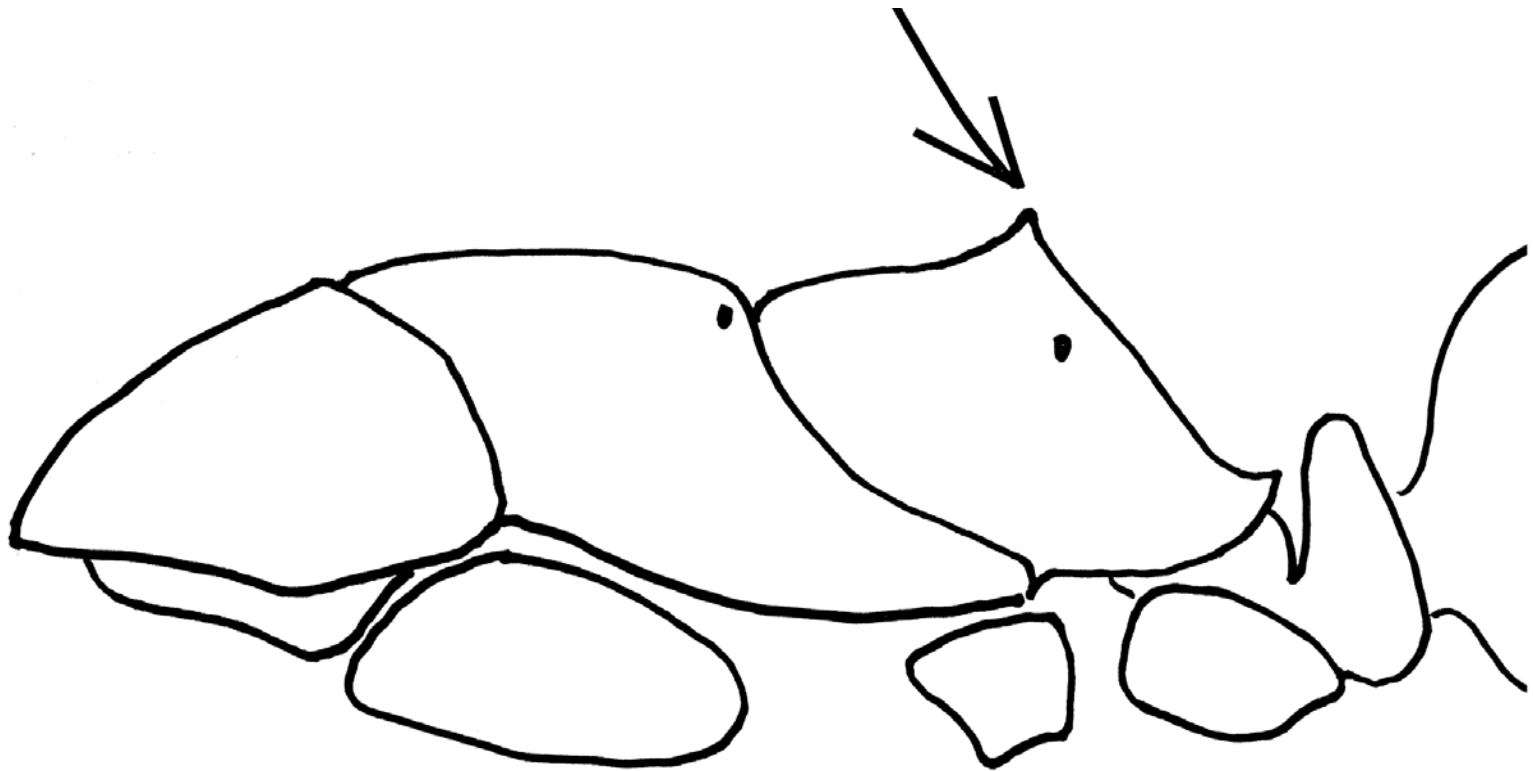


**Thorax with cone-shaped bump near node**

**Tórax con protuberancia en forma de cono cerca del nudo**



Dr Sean O'Keefe

4a